

Original Article

Endovascular stent implantation for aortic coarctation: parameters affecting clinical outcomes

Ibrahim Hatoum^{1*}, Raymond N Haddad^{2*}, Zakhia Saliba³, Toni Abdel Massih¹

¹Department of Cardiology, Hotel Dieu de France University Medical Center, Saint Joseph University, Beirut, Lebanon; ²Department of Pediatrics, Hotel Dieu de France University Medical Center, Saint Joseph University, Beirut, Lebanon; ³Department of Pediatric Cardiology, Hotel Dieu de France University Medical Center, Saint Joseph University, Beirut, Lebanon. *Equal contributors.

Received August 21, 2020; Accepted November 30, 2020; Epub December 15, 2020; Published December 30, 2020

Abstract: Objective: To evaluate safety and efficacy of endovascular stenting for aortic coarctation (AC) and to explore the effect of clinical parameters and stent characteristics on outcomes. Material and methods: Clinical data of all patients with AC who had attempted transcatheter stenting between 2004 and 2019 were retrospectively reviewed. Eligible patients had native or recurrent AC with systemic arterial hypertension and resting arm-leg pressure gradient > 20 mmHg. Exclusions included distance between takeoff of cervical arteries and stenotic aortic lesion < 10 mm, contraindication to antithrombotic therapy, bodyweight < 25 kg, and secondary hypertension. Results: A total of 20 patients (75.0% with native lesions) were included with a mean age of 18.4 years and a mean bodyweight of 59.2 kg. Procedure was successful in 90.0% of cases with an immediate drop in the invasive pressure gradient across lesions. On a median follow-up of 12 months (range, 8 to 144.9 months), coarctation reoccurred in five patients, but four of them required intervention after a median of 104.4 months with successful outcomes. Cheatham Platinum stents were significantly associated with lower rates of recoarctations and reinterventions. At the latest follow-up, three out of six patients with persistent hypertension had no recoarctation. Analysis showed that the need for antihypertensive therapy was not influenced by clinical parameters, aortic arch geometry, or stent characteristics. Conclusion: Treating AC with stent implantation is a safe and successful procedure. Using Cheatham Platinum stents appears to be associated with better outcomes. The persistence of arterial hypertension despite successful stenting remains a complex and challenging phenomenon.

Keywords: Congenital heart disease, aortic coarctation, stent, outcomes, hypertension

Introduction

Aortic coarctation (AC) is a relatively common congenital heart disease with male predominance [1]. It can occur as an isolated lesion but is often associated with other heart lesions. The AC is defined as a localized narrowing of aortic lumen commonly located opposite to PDA insertion. Infrequently, it can exist in the transverse aortic arch or be part of a long segment arch hypoplasia. The symptoms of AC depend on the severity of the condition. In some cases, the condition might not be detected until adulthood with hypertension being the usual presentation. The first-line treatment of native or recurrent symptomatic presentations was based on surgery since 1944 [2]. With the

improvements in transcatheter approach, balloon angioplasty, and more recently stent technology, endovascular stenting appears as an attractive less invasive alternative, especially for adolescents and adult patients [3]. Several authors reported that procedural success and long-term outcomes following stent therapy can be influenced by different parameters, yet with many controversial results [4-6]. More recent studies showed that balloon-expandable stents [7], lower body mass index, longer stent length, and Gothic arch geometry [8] were associated with worse procedure outcomes. Therefore, we aim to evaluate our local experience in AC stenting and to explore the clinical and stent characteristics affecting our mid-term outcomes.

Aortic coarctation stenting

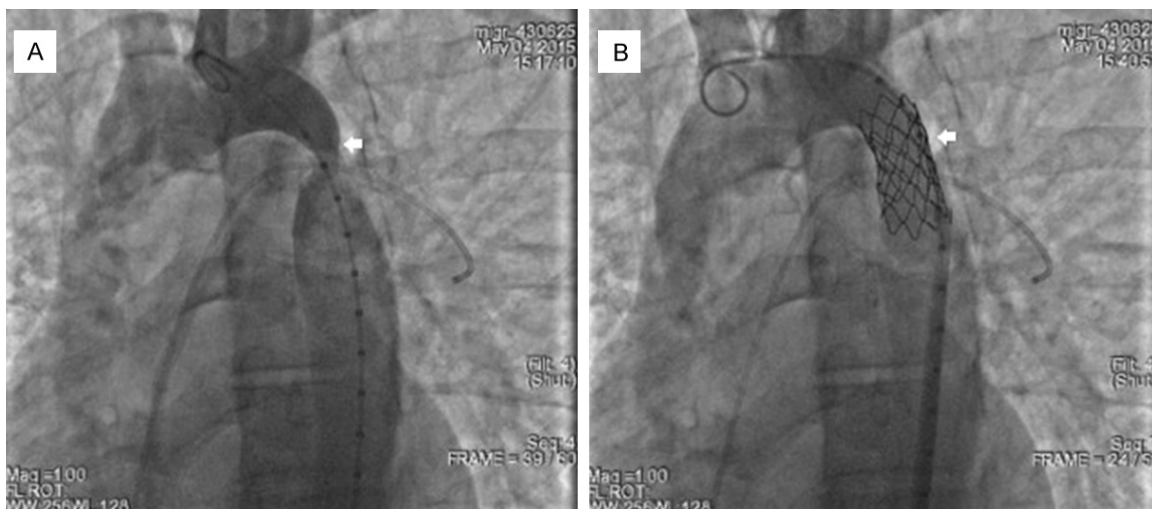

Figure 1. 30° Left anterior oblique projection aortography in a 21-year-old patient using a marked pigtail catheter. A. Before stent implantation: normal aortic arch anatomy followed by severely stenotic segment distant from the left subclavian artery. Note the JR catheter positioned in the left pulmonary artery and serving as a benchmark for accurate stent placement. B. A satisfactory anatomical result with no residual stenotic lesion and no parietal complication following implantation of a covered 39 mm long CP stent.

Methods

Study design and patients selection

All patients with AC and scheduled for attempted stent implantation at our institution between 2004 and April 2019 were retrospectively reviewed. Collected data included patient demographics, clinical and stent characteristics, and all procedure outcomes until the latest available follow-up. Patients eligible for stent implantation had native or recurrent AC associated with systemic arterial hypertension (highest of 4 limbs non-invasive arterial pressure > 130/80) and a resting non-invasive pressure gradient > 20 mmHg between upper and lower limbs [9]. Excluded patients had one of the following: (1) distance between the takeoff of cervical arteries and stenotic aortic lesion < 10 mm; (2) contraindication to antiplatelet or anticoagulation therapy; (3) body weight < 25 kg; and (4) other etiology of secondary hypertension. Study protocol was reviewed and approved by the institutional research ethics committee on human clinical research. Informed consent was signed by the patients or their legal guardians to perform the procedure after they were provided with a comprehensive explanation about the procedural details, the advantages, and possible complications.

Pre-stenting imaging

Before the intervention, transthoracic echocardiography (TTE) was performed on all patients

by the same experienced operator. A CT-scan angiogram was performed to assess the geometry of the aortic arch, the site and the degree of the obstruction, and its relationship with the great vessels. Complex anatomy was defined by the presence of one or more of the following criteria: (1) tortuous and/or quasi-atretic AC; (2) close lesion to the cervical arteries; (3) aortic aneurysm; and/or (4) sharply angulated (quasi-perpendicular) aortic arch. Blood pressure was recorded at all limbs and hypertension was defined according to standard recommendations [10, 11].

Catheterization technique

All interventions were performed by the same experienced operator in the catheterization laboratory under general anesthesia and fluoroscopic control. Prophylactic antibiotic therapy was given. One femoral arterial line was obtained for all patients using a 7-Fr short introducer. A radial artery approach was anticipated in challenging anatomies to cross the lesion from above and for the establishment of radial-femoral arterial rail to control stent deployment. One femoral venous line was obtained to place a Judkins right (JR) catheter (Cordis Corp., USA) in the left pulmonary artery and was used as a benchmark to the site of the coarctation in left anterior oblique projection (**Figure 1A**). After heparinization, a 5-Fr or 6-Fr JR catheter was transarterially introduced to measure the pressure gradient across the coarctation. The

Aortic coarctation stenting

Table 1. Patients' clinical characteristics, n=20

Variable	N (%)
Age groups at procedure	
Pediatric (< 16 years old)	9 (45.0)
Adult (≥ 16 years old)	11 (55.0)
Associated congenital heart defects*	10 (50.0)
ASD	1 (5.0)
VSD	2 (10.0)
BAV	8 (40.0)
Native coarctation	15 (75.0)
Coarctation geometry	
Romanesque	16 (80.0)
Gothic	4 (20.0)
Anatomical case	
Classical	15 (75.0)
Complex	5 (25.0)
Previous surgical repair	3 (15.0)
Previous balloon dilatation	3 (15.0)

*More than once choice applied. BSA: Body surface area; ASD: atrial septal defect, VSD: ventricular septal defect; BAV: bicuspid aortic valve.

JR catheter was exchanged for a 5F marked (pigtail or Multitrack) angiographic catheter over a 0.035-inch super Stiff J-curved Amplatz guidewire (Boston Scientific Corp., USA). Selective aortographies were adjusted in different projections for optimal measurement of the following structures: (1) diameter of the transverse aortic arch distal to the brachiocephalic artery; (2) diameter of the aorta directly above and below the lesion; (3) length and diameter of the coarctation; (4) distance between the coarctation and the cervical arteries; and (5) diameter of the descending aorta at the level of the diaphragm. The size of the balloon was chosen equal to that of the distal arch just after the origin of the subclavian artery. The stent length was chosen to adequately cover the lesion and if needed to treat isthmus hypoplasia. We preferred bare-metal stents as they are smaller in size (for the same balloon diameter) and to avoid jailing the cervical arteries. Covered stents were reserved for severe coarctation (especially when the selected balloon diameter was 3 times bigger than the narrowest aortic segment) and for aortic aneurysms. Assisted surgical vascular access was needed when 14-Fr was used or 12-Fr in younger patients. Over the wire, the balloon catheter with the stent mounted on it was advanced and positioned across the stenotic segment. The bal-

loon was manually inflated to deploy the stent and eliminate the waist on the balloon catheter. Pressure pullback tracings along with aortography were done to evaluate the results and to rule out aortic wall complications (**Figure 1B**). Procedure was declared successful when residual transaortic gradient was less than 10 mmHg [3]. After achieving femoral hemostasis by manual compression or surgical repair, adequate heparinization was administered for 24 hours. All patients were discharged after an overnight observation except in cases of failed procedures or severe complications. Oral aspirin was prescribed for 6 months. The next day, all patients underwent clinical examination with blood pressure measurement at all limbs, a blood test, and a chest X-ray to detect early complications. A twelve-lead electrocardiogram was done to ensure the sinus rhythm. A TTE was also performed to detect transaortic peak pressure gradient and any other early complication.

Follow-up protocol

Routine outpatient follow-ups were scheduled for 1 week then 1, 3, 6, and 12 months post-procedure and thereafter annually. A TTE was performed to detect residual or recurrent coarctation. A CT-scan angiogram was performed in failed or complicated procedures and when a recurrent coarctation was suspected. Blood pressure was assessed before any adjustment or discontinuation of antihypertensive therapy and was measured at all four limbs.

Statistical analysis

Statistical analyses were performed using the Statistical Package for the Social Sciences Statistics, version 22 for Macintosh (IBM, Armonk, NY, United States). Categorical variables were reported as frequency and percentage. Continuous variables are represented as mean with standard deviation or median with the range depending on the normality of distribution. The normality of measurements was assessed using skewness and kurtosis values and supported by the Shapiro-Wilk test. Statistical analysis for continuous variables was conducted using t-test or ANOVA test and Mann-Whitney U as appropriate and by Fisher's exact test for categorical variables. A *p*-value < 0.05 was considered statistically significant. All reported *p* values are two-sided.

Aortic coarctation stenting

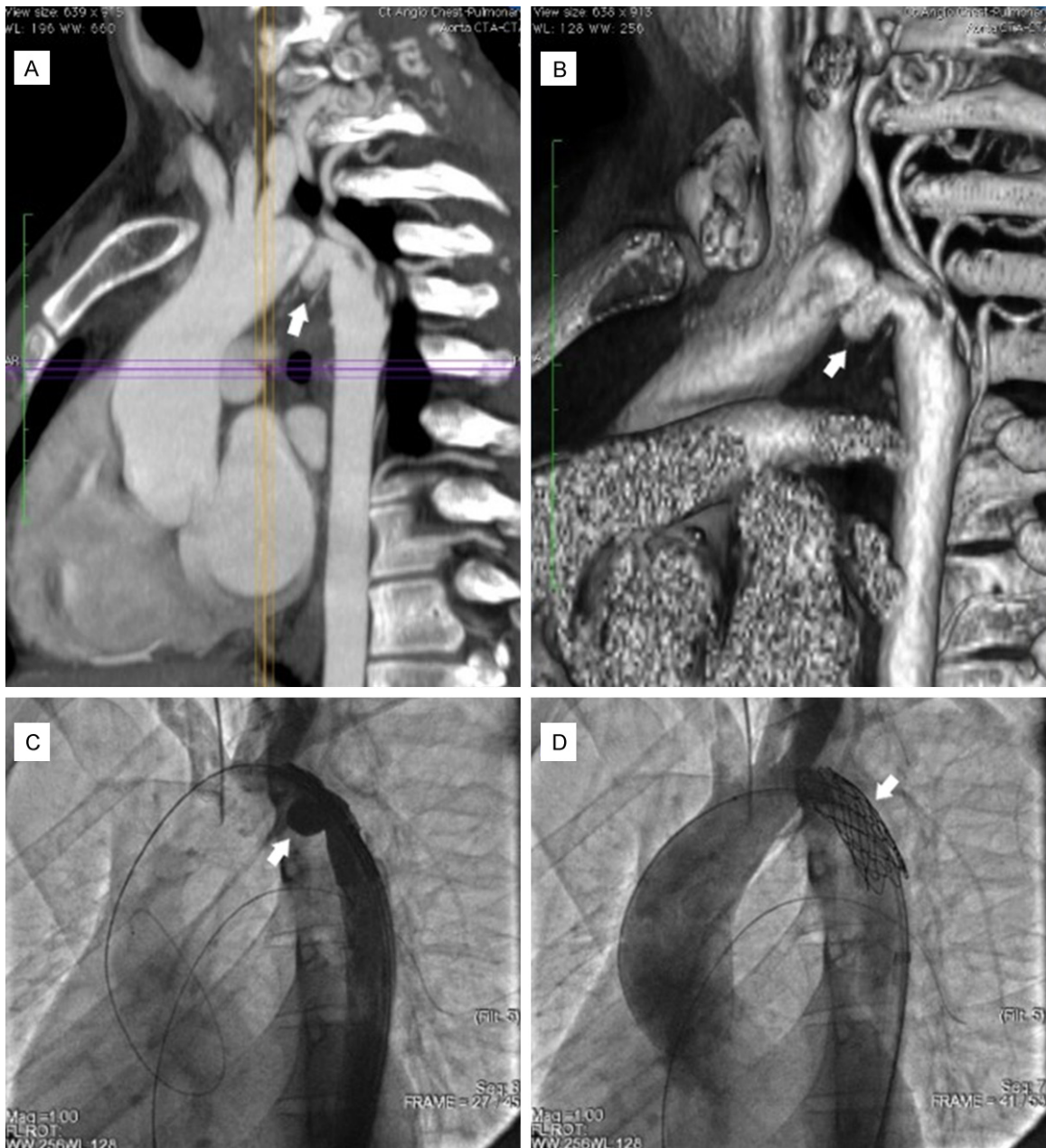


Figure 2. Complex aortic coarctation with very tortuous isthmus. A. Computerized tomography chest scan angiogram. B. Multiplanar reconstruction. C. Injection through the sheath to adjust a stent position upon deployment (30° left anterior oblique projection). D. Aortography after stent implantation with excellent results. Note the absence of parietal complication.

Results

Patients characteristics

A total of 20 patients (75.0% of males) were identified and included in the study. Demographics and clinical characteristics of the participants are summarized in **Table 1**. At the time of the intervention, patients' mean age was 18.4 ± 9.5 years (range, 3 to 38.9 ye-

ars) and the mean body weight was 59.2 ± 19.5 kg (range, 18 to 100 kg). Five patients presented with complex anatomical cases including a sharply angulated (quasi-perpendicular) aortic arch (n=1), an aortic aneurysm (n=1), a close lesion to the cervical arteries (n=1), and a tortuous and/or quasi-atretic AC (n=2) (**Figure 2**). The procedure was successful in 90.0% of patients and the success rate was higher in

Aortic coarctation stenting

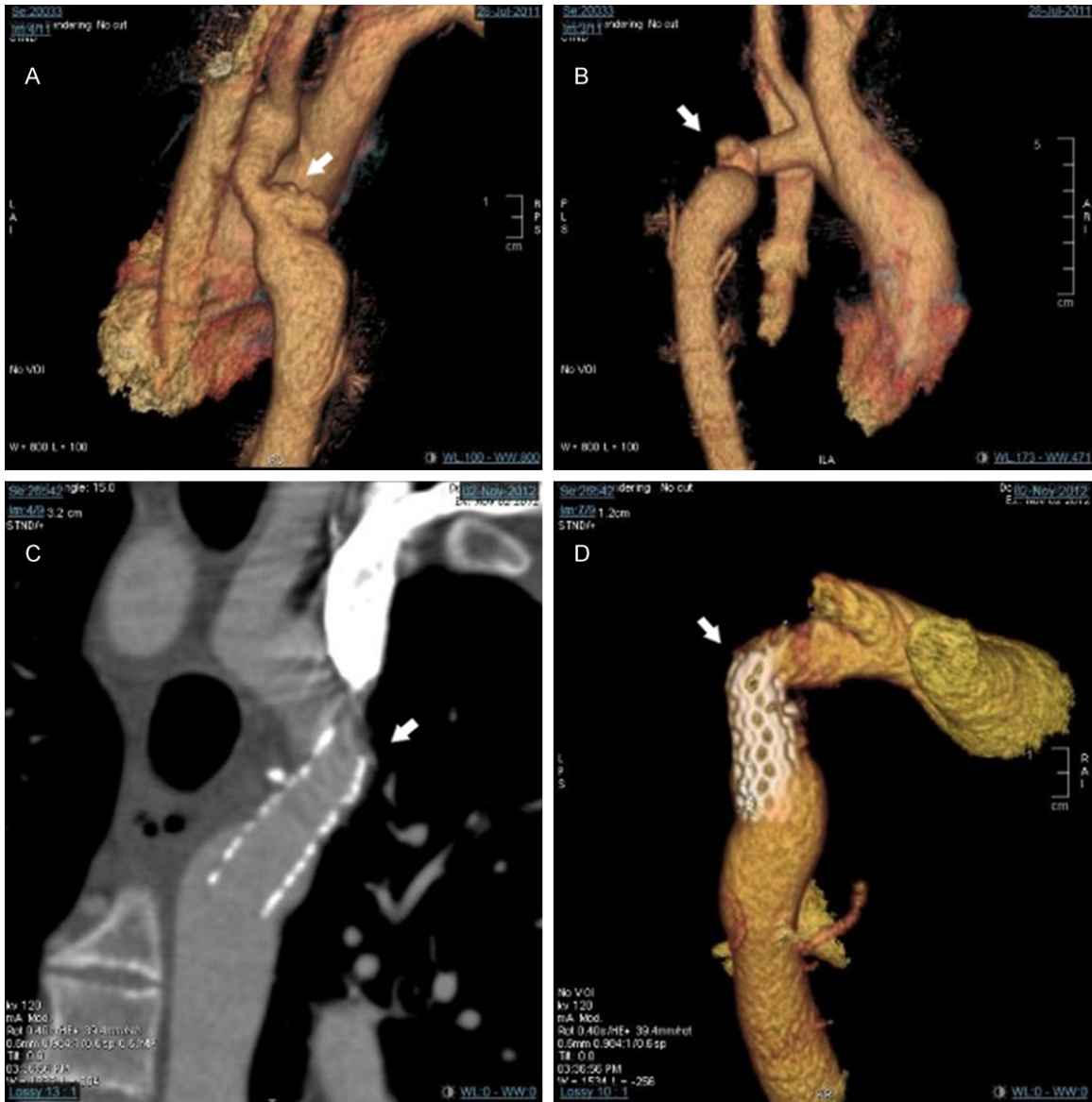


Figure 3. Computerized tomography chest scan angiogram with multiplanar reconstruction. A, B. Severe and short recoarctation with isthmic aneurysm of the posterior wall following surgical repair in a 17-year-old patient and repetitive ballooning. C, D. Same patient. Implantation of a 41 mm long Atrium covered stent premounted on a 14 mm balloon. Note stent displacement in the aortic arch leading to an iatrogenic coarctation.

patients with native AC and classical anatomical presentations. Failure occurred in two patients treated surgically twice before undergoing stent implantation. The first patient was a 17-year-old male who presented with a residual isthmic aneurysm of the aorta's posterior wall (**Figure 3A, 3B**). He was successfully treated using a covered stent but the procedure was complicated with an iatrogenic narrowing at the junction of the aortic arch and the descending aorta (**Figure 3C, 3D**). He underwent surgical

aortic by-pass and remained under anti-hypertensive therapy at the latest follow-up. The second patient was a highly symptomatic six-year-old boy with a 10 mm long quasi-atretic AC. The decision to treat this patient percutaneously was made when a third surgical repair was considered very risky. Although his procedure was declared unsuccessful, the invasive pressure gradient across the lesion dropped from 60 mmHg to 18 mmHg, and the patient became asymptomatic.

Aortic coarctation stenting

Table 2. Procedure-related data, n=20

Variable	N (%) or M ± SD (range)
Assisted (Cutdown) Vascular access	5 (25.0)
Radial artery approach	2 (10.0)
Primary ballooning	1 (5.0)
Stent characteristics	
CP	13 (65.0)
BMS	14 (70.0)
Premounted	5 (25.0)
Stent length (mm)	33.4 ± 7 (20-45)
Stent length indexed to height (mm/m)	20.7 ± 2.9 (14.4-25.7)
Stent length indexed to BSA (mm/m ²)	21.4 ± 4.4 (13-29.6)
Stent diameter (mm)	14.1 ± 2.8 (8-20)
Total procedural time, sheath in-out (min)	90 ± 24.2 (60-145)
Fluoroscopy time (min), median (range)	11.4 (7.5-31.6)

M ± SD: Mean ± Standard deviation; CP: Cheatham platinum; BMS: bare-metal stent; BSA: Body surface area.

Table 3. Procedure outcomes

Variable	N (%) or median (range)
Peripheral artery complication	1 (5.0)
Procedural success	18 (90.0)
Follow-up duration (months)	12 (8-144.9)
Persistent hypertension without coarctation, n=18	3 (15.0)
Recoarctation, n=18	5 (27.8)
Time to re-intervention (months)	104.4 (65-144.6)
Reinterventions, n=18	4 (22.2)
Stent redilatation	4 (22.2)
Re-stenting	--
Surgery	--
Mortality	0 (0)

Procedure outcomes

Procedure data and outcomes are summarized in **Tables 2** and **3**. An immediate reduction in the median invasive pressure gradient across the coarctation from 50 mmHg (range, 25-70 mmHg) to no gradient (range, 0-30 mmHg) was recorded after stent implantation. In total, 14 stents were bare-metal: 10 Cheatham Platinum (CP) (NuMED Inc., USA), 3 Genesis Cordis (Cordis Corp., USA), and one Cook Formula (Cook Medical, USA). Six stents were covered: 3 CP and 3 Advanta V12 (Atrium Medical Corp, USA). One pseudo-aneurysm formation of the left femoral artery was detected in a 23-year-old patient and was surgically treated without sequelae. On a median follow-up of 12 months,

mild re-coarctation occurred in five patients, but only four of them required intervention and were successfully treated with stent redilatation after a median of 104.4 months. Procedure outcomes and the need for reinterventions were assessed according to the clinical parameters as well as stent characteristics (**Figure 4**). All CP stents were successfully implanted and were significantly associated with lower rates of recoarctations and reinterventions. Before the procedure, all patients had arterial hypertension and seven among them were under anti-hypertensive drugs. This rate progressively decreased after aortic stenting so that only 6/20 (30.0%) patients were still hypertensive at the latest follow-up (**Figure 5**). Among those hypertensive patients, three subjects treated with CP, (bare-metal and hand-mounted) stents did not present any clinical sign of recoarctation. The analysis also showed that the need for antihypertensive therapy was not influenced by clinical parameters or by stent characteristics.

Discussion

Aortic coarctation is one of the most common congenital heart defects associated with high rates

of morbidity and mortality if left untreated, mainly mediated by uncontrolled hypertension [9]. Percutaneous stent placement had widely replaced traditional open surgery as the first-line treatment of native or recurrent coarctation of the aorta. Yet, many factors that may influence the rates of post-stenting residual hypertension, complications, and morbidity need to be elucidated [3].

In our present study, the implantation procedure was successful in 90.0% of patients. This success rate seems to be similar to the one reported by Bassiri [12] but slightly lower than the one stated by the Congenital Cardiovascular Interventional Study Consortium [13]. A mortality rate of 0.7% was reported in the Valvulo-

Aortic coarctation stenting

	Procedural success n=20	P	Procedure outcome, n=18			P	Reintervention n=18	P
			RC	HTN without RC	No HTN or RC			
Age groups								
Pediatric patients	8 (88.9)	1.000 ^a	3 (60.0)	1 (33.3)	4 (40.0)	0.827 ^a	3 (37.5)	0.275 ^a
Adults	10 (90.9)		2 (40.0)	2 (66.7)	6 (60.0)		1 (10.0)	
Coarctation type								
Native	15 (100.0)	0.053 ^a	5 (100.0)	2 (66.7)	8 (80.0)	0.540 ^a	4 (26.7)	1.000 ^a
Post-surgical	3 (60.0)		--	1 (33.3)	2 (20.0)		--	
Aortic cross geometry								
Roman	13 (81.3)	1.000 ^a	4 (80.0)	3 (100.0)	7 (70.0)	0.779 ^a	3 (21.4)	1.000 ^a
Gothic	4 (100.0)		1 (20.0)	--	3 (30.0)		1 (25.0)	
Anatomical case								
Classical	15 (100.0)	0.053 ^a	5 (100.0)	3 (100.0)	7 (70.0)	0.375 ^a	4 (26.7)	1.000 ^a
Complex	3 (60.0)		--	--	3 (30.0)		--	
Stent model								
CP	13 (100.0)	0.111 ^a	1 (20.0)	3 (100.0)	9 (90.0)	0.023^a	--	0.002^a
Non-CP	5 (71.4)		4 (80.0)	--	1 (10.0)		4 (80.0)	
Stent type (1)								
Covered	5 (83.3)	0.521 ^a	1 (20.0)	--	4 (40.0)	0.492 ^a	1 (20.0)	1.000 ^a
BMS	13 (92.9)		4 (80.0)	3 (100.0)	6 (60.0)		3 (23.1)	
Stent type (2)								
Premounted	3 (60.0)	0.053 ^a	1 (20.0)	--	2 (20.0)	1.000 ^a	1 (33.3)	1.000 ^a
Hand-mounted	15 (100.0)		4 (80.0)	3 (100.0)	8 (80.0)		3 (20.0)	

CP: Cheatham platinum; BMS: bare-metal stent; HTN: Hypertension; RC: Recoarctation.

^a: Fisher exact test

Bold values are significant P-values

Figure 4. Distribution of primary outcomes according to the different clinical parameters and stent characteristics.

	Pre-stenting	At discharge	At the latest follow-up
Anti-hypertensive therapy, N (%)[*]	7 (35.0)	6 (30.0)	4 (20.0)
Diuretics	1 (5.0)	1 (5.0)	--
CCB	4 (20.0)	3 (15.0)	1 (5.0)
ACEI	2 (10.0)	3 (15.0)	3 (15.0)
ARB	1 (5.0)	1 (5.0)	--
BB	3 (15.0)	4 (20.0)	2 (10.0)
Hypertension, N (%)	20 (100.0)	9 (45.0)	6 (30.0)
Non-invasive SBP (mmHg), median (range)	143 (120 – 200)	130 (103 – 165)	120 (100 – 170)
Non-invasive DBP (mmHg), median (range)	82 (60 – 120)	79 (50 – 100)	60 (50 – 120)
TAG on CUS (mmHg), mean ± SD (range)	64 ± 14 (46 – 98)	24 ± 18 (0 – 74)	22.4 ± 16.8 (0 – 64)

CCB: calcium channel blockers; ACEI: angiotensin-converting enzyme inhibitor; ARB: Angiotensin II receptor blockers; BB: Beta-blockers; SBP: systolic blood pressure; DBP: diastolic blood pressure; TAG: trans-aortic gradient

Figure 5. Evolution of the transaortic gradient, hypertension, and treatment across follow-up.

plasty and Angioplasty of Congenital Anomalies registry and was attributed to patients' comorbidities rather than stenting procedure [14]. Our results were consistent with these findings, indicating that stent implantation is a safe procedure. Several authors reported that aortic stenting success rate could be affected by the aorta's anatomical characteristics [8] and by stenting techniques [7, 15, 16]. Our results showed that all patients with native lesions, and in whom hand-mounted or CP stents were used, experienced successful procedures (Figure 4). Although these findings did not reach statistical significance, we believe that proper patient selection with native and focal coarctation as well as proper stent type could lead to better procedural outcomes [5, 7, 15, 16].

Unsurprisingly, 45.0% of our patients had residual arterial hypertension at discharge date, which is comparable to the rate of residual hypertension in the COAST study [17]. However, on a median follow-up of 12 months, this rate progressively decreased to 30.0% which is quite similar to the one following AC surgical repair [18]. Therefore, we can conclude that following aortic stenting, normal blood pressure status may be achieved during medium-term follow-up [19] since arterial baroreceptors need several months to adapt to the new hemodynamic status achieved after eliminating aortic stenosis [8].

After a successful procedure, recoarctation occurred in five patients (27.8%) and four of them were treated percutaneously with excellent outcomes. We noticed that 80% of this

phenomenon occurred in patients treated with exclusively non-CP bare-metal stents ($P=0.023$). Some studies showed a similar recoarctation rate [20, 21], however, in other ones where covered CP stents were exclusively used, lower rates were reported [15, 22]. The CP stents with the 8-zig conformation are designed to minimize aortic wall injury which makes them the optimal choice for implantation in narrowed segments [15, 23-25]. Additionally, recoarctation occurred more frequently in younger patients and could be related to arterial growth, yet no statistical significance was identified. The median time to reintervention in our population was 104.4 months, similar to other studies [3, 26], indicating that procedure outcomes are sustainable over time, especially in patients treated with CP stents ($P=0.023$) (**Figure 4**). When compared to premounted stents, treating AC using hand-mounted stents significantly decreases post-procedural transaortic invasive gradient from a median of 10 mmHg to no gradient ($P=0.015$). This finding is consistent with the results reported by other studies [27, 28].

Finally, the mean trans-aortic gradient at the last follow-up was 22.4 ± 16.8 mmHg, which is similar to what was found in other studies [23, 29]. On follow-up, we also witnessed that the non-invasive trans-aortic gradient tends to be lower in native lesions, and when CP stents were used. Yet, despite the normalization of the gradient, arterial hypertension was still present in four patients without any sign of clinical recoarctation. This may be explained by the fact that AC is not a focal disease consisting of aortic arch narrowing [14, 30] and could be associated with other aortic and vascular intrinsic factors leading to persistent arterial hypertension even after appropriate treatment [8].

Study limitations

This is a single-center retrospective study with a relatively limited number of patients. Multivariate analysis was not possible and this could be related to unbalanced group sizes.

Conclusion

Stent implantation is a feasible, and safe procedure for relieving aortic narrowing and improving clinical outcomes, with few morbidities. The persistence of hypertension after success-

ful stenting remains the challenge with complex underlying physiopathology and motivates a lifetime monitoring.

Disclosure of conflict of interest

None.

Author contributions

RH designed the study, performed all statistical calculations, analyzed and critically interpreted the results. RH took the lead with IH in writing the manuscript. All authors discussed the results, read and approved the final manuscript.

Address correspondence to: Dr. Raymond N Haddad, Department of Pediatrics, Hotel Dieu de France University Medical Center, Saint Joseph University, Alfred Naccache Boulevard, Achrafieh, Beirut 166830, Lebanon. Tel: +33 7 53 15 95 04; +961 70 605 800; E-mail: raymondhaddad@live.com

References

- [1] Warmerdam EG, Krings GJ, Meijs TA, Franken AC, Driesen BW, Sieswerda GT, Meijboom FJ, Doevendans PAF, Molenschot MMC and Voskuil M. Safety and efficacy of stenting for aortic arch hypoplasia in patients with coarctation of the aorta. *Neth Heart J* 2020; 28: 145-152.
- [2] Cohen M, Fuster V, Steele PM, Driscoll D and McGoon DC. Coarctation of the aorta. Long-term follow-up and prediction of outcome after surgical correction. *Circulation* 1989; 80: 840-845.
- [3] Forbes TJ, Kim DW, Du W, Turner DR, Holzer R, Amin Z, Hijazi Z, Ghasemi A, Rome JJ, Nykanen D, Zahn E, Cowley C, Hoyer M, Waight D, Gruenstein D, Javois A, Foerster S, Kreutzer J, Sullivan N, Khan A, Owada C, Hagler D, Lim S, Canter J and Zellers T; CCISC Investigators. Comparison of surgical, stent, and balloon angioplasty treatment of native coarctation of the aorta: an observational study by the CCISC (Congenital Cardiovascular Interventional Study Consortium). *J Am Coll Cardiol* 2011; 58: 2664-2674.
- [4] Eicken A, Pensl U, Sebening W, Hager A, Genz T, Schreiber C, Lang D, Kaemmerer H, Busch R and Hess J. The fate of systemic blood pressure in patients after effectively stented coarctation. *Eur Heart J* 2006; 27: 1100-1105.
- [5] Tyagi S, Singh S, Mukhopadhyay S and Kaul UA. Self- and balloon-expandable stent implantation for severe native coarctation of aorta in adults. *Am Heart J* 2003; 146: 920-928.

Aortic coarctation stenting

- [6] Ou P, Bonnet D, Auriacombe L, Pedroni E, Ballex F, Sidi D and Mousseaux E. Late systemic hypertension and aortic arch geometry after successful repair of coarctation of the aorta. *Eur Heart J* 2004; 25: 1853-1859.
- [7] Firoozi A, Mohebbi B, Noohi F, Bassiri H, Mohebbi A, Abdi S, Maleki M, Shafe O, Peighambari MM, Alemzadeh-Ansari MJ, Bakhshandeh H, Rezaei Y and Sepehrvand N. Self-expanding versus balloon-expandable stents in patients with isthmic coarctation of the aorta. *Am J Cardiol* 2018; 122: 1062-1067.
- [8] Iriart X, Laik J, Cremer A, Martin C, Pillois X, Jalal Z, Roubertie F and Thambo JB. Predictive factors for residual hypertension following aortic coarctation stenting. *J Clin Hypertens (Greenwich)* 2019; 21: 291-298.
- [9] Warnes CA, Williams RG, Bashore TM, Child JS, Connolly HM, Dearani JA, del Nido P, Fasules JW, Graham TP Jr, Hijazi ZM, Hunt SA, King ME, Landzberg MJ, Miner PD, Radford MJ, Walsh EP and Webb GD. ACC/AHA 2008 guidelines for the management of adults with congenital heart disease: a report of the American college of cardiology/American heart association task force on practice guidelines (writing committee to develop guidelines on the management of adults with congenital heart disease). *J Am Coll Cardiol* 2008; 52: e143-e263.
- [10] Whelton PK, Carey RM, Aronow WS, Casey DE Jr, Collins KJ, Dennison Himmelfarb C, DePalma SM, Gidding S, Jamerson KA, Jones DW, MacLaughlin EJ, Muntner P, Ovbiagele B, Smith SC Jr, Spencer CC, Stafford RS, Taler SJ, Thomas RJ, Williams KA Sr, Williamson JD and Wright JT Jr. 2017 ACC/AHA/AAPA/ABC/ACPM/AGS/APhA/ASH/ASPC/NMA/PCNA guideline for the prevention, detection, evaluation, and management of high blood pressure in adults: a report of the American college of cardiology/American heart association task force on clinical practice guidelines. *J Am Coll Cardiol* 2018; 71: e127-e248.
- [11] Flynn JT, Kaelber DC, Baker-Smith CM, Blowey D, Carroll AE, Daniels SR, de Ferranti SD, Dionne JM, Falkner B, Flinn SK, Gidding SS, Goodwin C, Leu MG, Powers ME, Rea C, Samuels J, Simasek M, Thaker VV and Urbina EM; SUBCOMMITTEE ON SCREENING AND MANAGEMENT OF HIGH BLOOD PRESSURE IN CHILDREN. Clinical practice guideline for screening and management of high blood pressure in children and adolescents. *Pediatrics* 2017; 140: e20171904.
- [12] Bassiri HA, Abdi S, Shafe O and Sarpooshi J. Early and midterm results following interventional coarctoplasty: evaluation of variables that can affect the results. *Korean Circ J* 2017; 47: 97-106.
- [13] Forbes TJ, Garekar S, Amin Z, Zahn EM, Nykanen D, Moore P, Qureshi SA, Cheatham JP, Ebeid MR, Hijazi ZM, Sandhu S, Hagler DJ, Sievert H, Fagan TE, Ringewald J, Du W, Tang L, Wax DF, Rhodes J, Johnston TA, Jones TK, Turner DR, Pedra CA and Hellenbrand WE; Congenital Cardiovascular Interventional Study Consortium (CCISC). Procedural results and acute complications in stenting native and recurrent coarctation of the aorta in patients over 4 years of age: a multi-institutional study. *Catheter Cardiovasc Interv* 2007; 70: 276-285.
- [14] McCrindle BW, Jones TK, Morrow WR, Hagler DJ, Lloyd TR, Nouri S and Latson LA. Acute results of balloon angioplasty of native coarctation versus recurrent aortic obstruction are equivalent. Valvuloplasty and Angioplasty of Congenital Anomalies (VACA) registry investigators. *J Am Coll Cardiol* 1996; 28: 1810-1817.
- [15] Sohrabi B, Jamshidi P, Yaghoubi A, Habibzadeh A, Hashemi-Aghdam Y, Moin A, Kazemi B, Ghaffari S, Abdolazadeh Baghayi MR and Mahmoodi K. Comparison between covered and bare Cheatham-Platinum stents for endovascular treatment of patients with native post-ductal aortic coarctation immediate and intermediate-term results. *JACC Cardiovasc Interv* 2014; 7: 416-423.
- [16] Taggart NW, Minahan M, Cabalka AK, Cetta F, Usmani K and Ringel RE; COASOT II Investigators. Immediate outcomes of covered stent placement for treatment or prevention of aortic wall injury associated with coarctation of the aorta (COAST II). *JACC Cardiovasc Interv* 2016; 9: 484-493.
- [17] Meadows J, Minahan M, McElhinney DB, McEnaney K and Ringel R; COAST Investigators. Intermediate outcomes in the prospective, multicenter coarctation of the aorta stent trial (COAST). *Circulation* 2015; 131: 1656-1664.
- [18] Maron BJ, Humphries JO, Rowe RD and Mellits ED. Prognosis of surgically corrected coarctation of the aorta. A 20 year postoperative appraisal. *Circulation* 1973; 47: 119-126.
- [19] Meijs TA, Warmerdam EG, Slieker MG, Krings GJ, Molenschot MMC, Meijboom FJ, Sieswerda GT, Doevendans PA, Bouma BJ, de Winter RJ, Mulder BJM and Voskuil M. Medium-term systemic blood pressure after stenting of aortic coarctation: a systematic review and meta-analysis. *Heart* 2019; 105: 1464-1470.
- [20] Presbitero P, Demarie D, Villani M, Actis Perinetti E, Riva G, Orzan F, Bobbio M, Morea M and Brusca A. Long term results (15 to 30 years) of surgical repair of aortic coarctation. *Br Heart J* 1987; 57: 462-467.
- [21] del Cerro MJ, Fernández-Ruiz A, Benito F, Rubio D, Castro MC and Moreno F. Balloon angio-

Aortic coarctation stenting

- plasty for native coarctation in children: immediate and medium-term results. *Rev Esp Cardiol* 2005; 58: 1054-1061.
- [22] Butera G, Piazza L, Chessa M, Negura DG, Rosti L, Abella R, Delogu A, Condoluci C, Magherini A and Carminati M. Covered stents in patients with complex aortic coarctations. *Am Heart J* 2007; 154: 795-800.
- [23] San Norberto García EM, González-Fajardo JA, Gutiérrez V, Fernández B, San Román A and Vaquero C. Open surgical repair and endovascular treatment in adult coarctation of the aorta. *Ann Vasc Surg* 2010; 24: 1068-1074.
- [24] Ringel RE, Gauvreau K, Moses H and Jenkins KJ. Coarctation of the Aorta Stent Trial (COAST): study design and rationale. *Am Heart J* 2012; 164: 7-13.
- [25] Ewert P, Schubert S, Peters B, Abdul-Khaliq H, Nagdyman N and Lange PE. The CP stent-short, long, covered—for the treatment of aortic coarctation, stenosis of pulmonary arteries and caval veins, and Fontan anastomosis in children and adults: an evaluation of 60 stents in 53 patients. *Heart* 2005; 91: 948-953.
- [26] Erben Y, Oderich GS, Verhagen HJM, Witsenburg M, van den Hoven AT, Debus ES, Kölbel T, Arko FR 3rd, Torsello GB, Torsello GF, Lawrence PF, Harlander-Locke MP, Bacharach JM, Jordan WD Jr, Eskandari MK and Hagler DJ. Multicenter experience with endovascular treatment of aortic coarctation in adults. *J Vasc Surg* 2019; 69: 671-679.
- [27] Boe BA, Zampi JD, Schumacher KR, Yu S and Armstrong AK. The use and outcomes of small, medium and large premounted stents in pediatric and congenital heart disease. *Pediatr Cardiol* 2016; 37: 1525-1533.
- [28] Meadows J, Teitel D and Moore P. Use and performance of premounted stents compared to nonpremounted stents in pediatric and adult congenital cardiac catheterization. *J Interv Cardiol* 2013; 26: 58-61.
- [29] Ostovan MA, Kojuri J, Mokhtaryan M, Razazi V and Zolghadrasli A. Procedural outcome and one year follow up of patients undergoing endovascular stenting for coarctation of aorta: a single center study. *J Cardiovasc Thorac Res* 2014; 6: 117-121.
- [30] Róg B, Okólska M, Dziedzic-Oleksy H, Sałapa K, Rubiś P, Kopec G, Podolec P and Tomkiewicz-Pajak L. Arterial stiffness in adult patients after coarctation of aorta repair and with bicuspid aortic valve. *Acta Cardiol* 2019; 74: 517-524.