

## Original Article

# Intracardiac echocardiography versus transesophageal echocardiography for left atrial appendage closure: an updated meta-analysis and systematic review

Aravdeep Jhand<sup>1</sup>, Abhishek Thandra<sup>2</sup>, Yeongjin Gwon<sup>3</sup>, Mohit K Turagam<sup>4</sup>, Mahi Ashwath<sup>5</sup>, Pradeep Yadav<sup>6</sup>, Fawaz Alenezi<sup>7</sup>, Jalal Garg<sup>8</sup>, J Dawn Abbott<sup>9</sup>, Dhanunjaya Lakkireddy<sup>10</sup>, Manish Parikh<sup>11</sup>, Robert Sommer<sup>12</sup>, Poonam Velagapudi<sup>1</sup>

<sup>1</sup>Division of Cardiology, University of Nebraska Medical Center, Omaha, NE, USA; <sup>2</sup>Division of Cardiology, Creighton University School of Medicine, Omaha, NE, USA; <sup>3</sup>Department of Biostatistics, College of Public Health, University of Nebraska Medical Center, Omaha, NE, USA; <sup>4</sup>Division of Cardiac Electrophysiology, Icahn School of Medicine at Mount Sinai, New York, NY, USA; <sup>5</sup>University of Iowa, Iowa City, IA, USA; <sup>6</sup>Interventional Cardiology, Marcus Heart Valve Center, Piedmont Hospital, Atlanta, GA, USA; <sup>7</sup>Duke University, Durham, NC, USA; <sup>8</sup>Division of Cardiovascular Medicine, Medical College Wisconsin, Milwaukee, WI, USA; <sup>9</sup>Division of Cardiology, Brown University, Providence, RI, USA; <sup>10</sup>Kansas City Heart Rhythm Institute and Research Foundation, Kansas City, KS, USA; <sup>11</sup>Weil Cornell Medicine, Brooklyn, NY, USA; <sup>12</sup>Division of Cardiology, Columbia University Medical Center, New York, NY, USA

Received July 30, 2020; Accepted November 30, 2020; Epub December 15, 2020; Published December 30, 2020

**Abstract:** Intracardiac echocardiography (ICE) has emerged as an alternative to transesophageal echocardiography (TEE) to guide implantation of percutaneous left atrial appendage closure (LAAC) devices in patients with atrial fibrillation (AF) and a high bleeding risk. We reviewed the efficacy and safety of ICE compared to TEE in LAAC in this updated meta-analysis. Medline, CINAHL, EMBASE and Scopus were systematically searched for studies comparing ICE and TEE in percutaneous LAAC. Our primary outcomes of interest were procedural success and study reported periprocedural complications. Secondary outcomes included various procedural characteristics. Risk ratios (RR), standardized mean differences (SMD) and their corresponding 95% confidence intervals (CI) were calculated. The analysis was performed using a random-effect model. Nine observational studies met our inclusion criteria with a total of 2620 patients (ICE: 679 and TEE: 1941). Mean CHA<sub>2</sub>DS<sub>2</sub>-Vasc ( $4.4 \pm 0.3$  for ICE vs  $4.5 \pm 0.3$  for TEE,  $P = 0.60$ ) and HAS-BLED ( $3.2 \pm 0.4$  vs  $3.1 \pm 0.6$ ,  $P = 0.78$ ) scores were comparable between the two groups. There was no significant difference in procedure success rate (RR: 1.01, 95% CI: 0.99-1.02,  $P = 0.31$ ) and periprocedural complications (RR: 0.85, 95% CI: 0.59-1.23,  $P = 0.39$ ). No significant difference was observed in procedure duration, fluoroscopy time and contrast volume used while a trend towards decreased hospital length of stay was seen with the use of ICE. Thus, our updated meta-analysis shows ICE is as effective and safe as TEE for implantation of LAAC devices.

**Keywords:** Intracardiac echocardiography, transesophageal echocardiography, left atrial appendage closure, watchman device, amplatzer cardiac plug, amulet

## Introduction

Nearly 90% of strokes in non-valvular atrial fibrillation (AF) originate from thrombus formation in the left atrial appendage (LAA) [1]. Oral anticoagulants (OAC) are the gold standard for prophylaxis against systemic thromboembolism. Based on results of two randomized clinical trials and multiple registries, percutaneous left atrial appendage closure (LAAC) devices such as Watchman and amplatzer cardiac plug

(ACP) have emerged as a feasible alternative for stroke prevention in AF [2-5]. Although, early Watchman experience was plagued with serious complications [6], registries and real-world data have demonstrated a lower rate of complications with increasing operator experience [7].

Successful deployment of LAAC devices involve pre-procedural planning utilizing imaging techniques such as cardiac computed tomography angiography (CCTA) or transesophageal echo-

**Table 1.** Newcastle Ottawa Scale for quality assessment of studies

Study	Selection	Comparability	Outcome	Total
Frangieh 2016	****	**	***	9
Korsholm 2017	****	**	***	9
Berti 2018	****	**	***	9
Hemam 2018	****	*	***	8
Kim 2018	****	**	***	9
Reis 2018	****		***	7
Nielsen-Kudsk 2019	****	**	***	9
Streb 2019	****	*	***	8
Alkhouli 2020	****	**	***	9

Each (\*) is equivalent to one point. The maximum score is 9 (\*\*\*\* for selection, \*\* for comparability, \*\*\* for outcome).

cardiography (TEE) [8]. These modalities allow the operator to not only rule out left atrial appendage (LAA) thrombus but also to identify appropriate size of LAAC device. Intraprocedural imaging with TEE remains the standard in guiding LAAC device across the interatrial septum into the left atrium (LA) and ensuring accurate deployment into LAA. TEE, however, requires endotracheal intubation and general anesthesia (GA) which may potentially increase the risk of complications and thus adversely impact patient satisfaction and outcomes. Intracardiac echocardiography (ICE) has evolved as a powerful imaging modality in structural heart interventions that eliminates the need for GA and can be performed under local anesthesia or moderate sedation. Various observational studies have explored the role of ICE in percutaneous LAAC but it appears to be underutilized [9]. We performed this updated meta-analysis to investigate whether ICE can be performed safely and effectively compared to TEE in percutaneous LAAC.

## Materials and methods

### Data source

A systematic search was performed without any language restriction in Pubmed, Cumulative Index to Nursing and Allied Health Literature (CINAHL), Excerpta Medica database (EMBASE) and Scopus from inception to June 25<sup>th</sup>, 2020 for studies comparing the use of ICE and TEE in LAAC. This systematic review and meta-analysis were performed in accordance with PRISMA (Preferred Reporting Items for Systematic Reviews and Meta-Analysis) guidelines [10].

### Search strategy

A varied combination of the following keywords were used in the search strategy: “left atrial appendage closure”, “LAAC”, “Watchman”, “Amplatzer cardiac plug”, “Amulet”, “atrial fibrillation”, “transesophageal echocardiography”, “TEE”, “intracardiac echocardiography” and “ICE”.

### Study selection

Following inclusion criteria were used for selecting relevant studies: 1) patients  $\geq 18$  years of age who received percutaneous LAAC using either Watchman, Amplatzer Cardiac Plug (ACP) or Amulet device. 2) studies compared the use of TEE vs ICE to guide deployment of LAAC device. 3) procedural success and complications were compared between TEE and ICE for LAAC. 4) full text publications were available. Studies were excluded if: 1) only abstracts were available without full text publications, and 2) data comparing outcomes between ICE and TEE were unavailable.

### Data extraction

Literature search was performed independently by two investigators (AJ and AT), followed by screening of studies for eligibility. Each investigator extracted data from eligible studies using a standardized data collection form. Any differences in the included studies and collected data were resolved through consensus after discussion with the senior author (PV). Data on study characteristics, baseline characteristics of included patients, procedural characteristics and complications were collected.

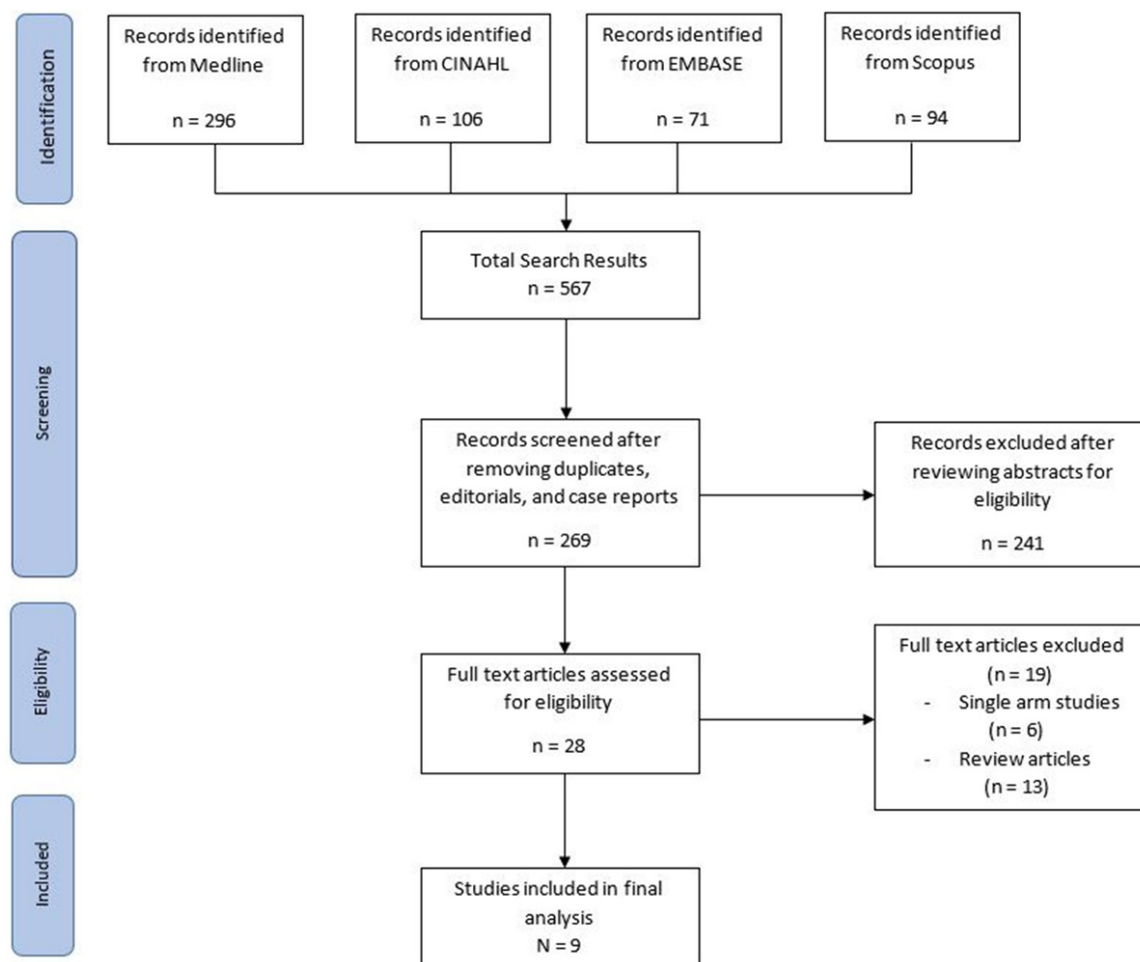
### Quality assessment of studies

Quality assessment of studies was performed using the Newcastle-Ottawa scale for observational studies (**Table 1**).

### Outcomes

Our co-primary outcomes of interest were procedural success which was defined as successful deployment of LAAC device with a per-device leak of  $\leq 5$  mm and study reported periprocedural complications (including pericardial effusion/tamponade, stroke, death,

## ICE vs TEE for LAAC



**Figure 1.** Flow diagram of the search strategy. CINAHL = Cumulative Index to Nursing and Allied Health Literature, EMBASE = Excerpta Medica database.

vascular complications, and device embolization). Secondary outcomes included procedural characteristics such as procedure duration, fluoroscopy time, contrast volume and length of hospital stay.

### Statistical analysis

Pooled analysis was presented as risk ratios (RR) and 95% confidence intervals (CI), which was calculated using Mantel-Haenszel method for dichotomous variables. Standardized mean differences (SMD) along with 95% CI were calculated for continuous variables using an inverse variance method. Higgins' and Thompson's  $I^2$  statistics were used for assessing heterogeneity among different studies, with  $I^2$  values of < 25%, 25-75% and > 75% corresponding to low, moderate and high levels of heterogeneity, respectively [11]. Publication

bias was estimated by visual inspection of funnel plots. A continuity correction of 0.5 was used for the zero events on ICE and TEE for periprocedural complications. The meta-analysis was performed using Review Manager (RevMan), version 5.3. (Copenhagen: The Nordic Cochrane Center, The Cochrane Collaboration).

### Results

#### Search results

A total of 567 records were initially identified following a thorough literature search. After removing duplicates, editorials, case reports and studies that did not meet our inclusion criteria, 9 observational studies were included in the final quantitative analysis (**Figure 1**) [12-20].

## ICE vs TEE for LAAC

**Table 2.** Characteristics of included studies

Study	N	Country	Single vs Multicenter	Type of study	Study period	LAAC device	Preprocedural imaging	Type of ICE catheter used	ICE catheter position
Frangieh 2016	76	Switzerland	Single	Retrospective	November 2013-June 2016	Watchman	TEE	AcuNav (Siemens Healthcare, Germany) 8F	LA
Korsholm 2017	216	Denmark	Single	Retrospective	March 2010-November 2016	ACP and Amulet	Cardiac CT	ViewFlex Xtra (St. Jude, USA) 9F	LA
Berti 2018	604	Italy	Multi	Retrospective	December 2008-April 2015	ACP and Amulet	TEE and Cardiac	AcuNav (Siemens Healthcare, Germany) 8F	RA or LA
Hemam 2018	104	USA	Multi	Retrospective	April 2015-January 2018	Watchman	N/A	AcuNav (Siemens Healthcare, Germany) and ViewFlex Xtra (St. Jude, USA)	LA
Kim 2018	144	Korea	Multi	Retrospective	March 2013-April 2017	Watchman, ACP and Amulet	TEE	AcuNav (Biosense Webster, USA) 8F	LSPV
Reis 2018	82	Portugal	Single	Retrospective	May 2010-January 2017	Watchman, ACP, and Amulet	TEE	N/A	LA
Nielsen-Kudsk 2019	1088	Global	Multi	Retrospective	June 2015-September 2016	Amulet	TEE or Cardiac CT	ViewFlex Xtra (Abbott Vascular, USA)	LSPV
Streb 2019	23	Poland	Single	Prospective	N/A	Amulet	TEE	AcuNav (Siemens Healthcare, USA) 8F	LA
Alkhouli 2020	286	USA	Single	Retrospective	June 2016-April 2019	Watchman	TEE or cardiac CT	AcuNav (Siemens Healthcare, USA) and ViewFlex Xtra (Abbott Vascular, USA) 10F	LA

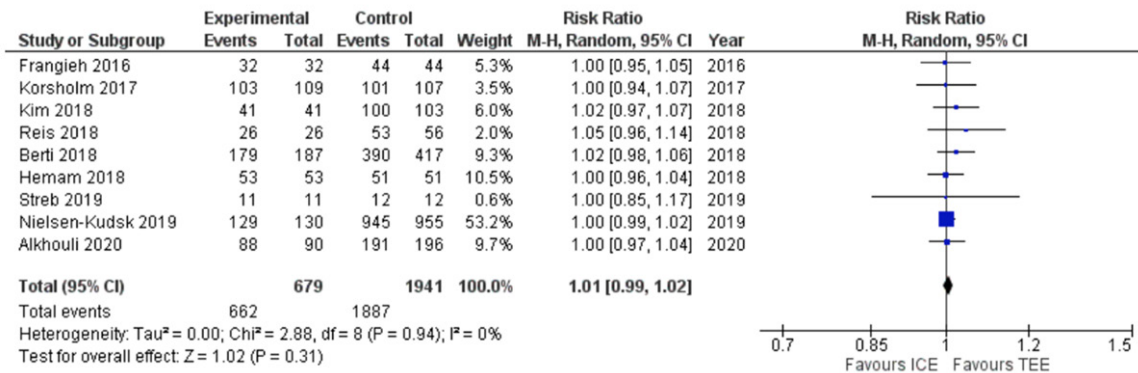
ACP = Amplatzer cardiac plug, CT = Computed tomography, F = French gauge, ICE = Intracardiac echocardiography, LA = Left atrium, LAAC = Left atrial appendage closure, LSPV = Left superior pulmonary vein, MI = Myocardial infarction, RA = Right atrium, TEE = Transesophageal echocardiography, TIA = Transient ischemic attack, USA = United States of America.

**Table 3.** Baseline characteristics of the patient population in the included studies

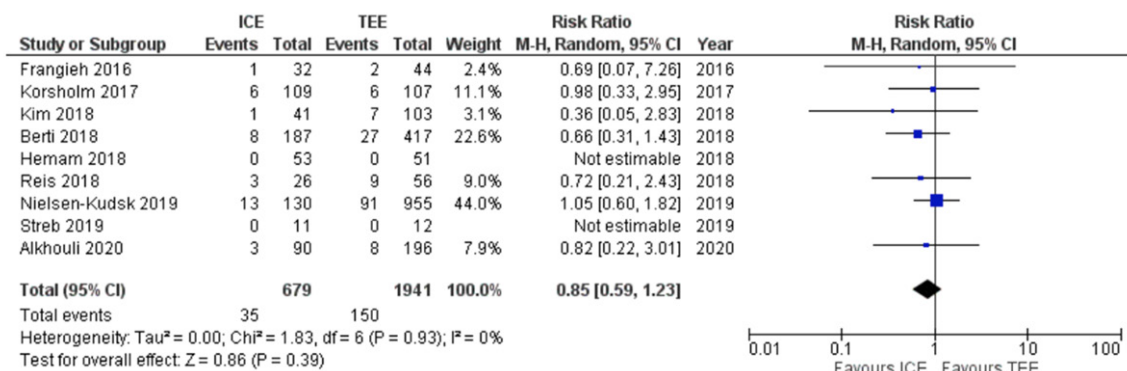
Study		Age	Female	Hypertension	Diabetes Mellitus	History of Stroke/TIA	Prior Bleeding	CHA <sub>2</sub> DS <sub>2</sub> -Vasc score	HAS-BLED Score
Frangieh 2016	ICE (n = 32)	76 [68-80]	6 (19%)	27 (84%)	14 (44%)	9 (28%)	19 (59%)	4 [3-5.8]	3 [3-4]
	TEE (n = 44)	81 [75-85]	19 (43%)	38 (86%)	16 (36%)	9 (21%)	14 (32%)	4 [3-5]	3 [3-4.8]
Korsholm 2017	ICE (n = 109)	73.0 ± 7.8	41 (38%)	91 (83%)	23 (21%)	50 (46%)	94 (86%)	4.1 ± 1.6	4.1 ± 0.9
	TEE (n = 107)	73.0 ± 9.7	28 (26%)	86 (80%)	23 (22%)	59 (55%)	86 (80%)	4.4 ± 1.6	4.1 ± 1.1
Berti 2018	ICE (n = 187)	76 ± 8	64 (34%)	N/A	N/A	N/A	N/A	4.3 ± 1.4	3.2 ± 1.4
	TEE (n = 417)	74 ± 7	146 (35%)	N/A	N/A	N/A	N/A	4.2 ± 1.4	3.1 ± 1.1
Hemam 2018	ICE (n = 53)	77 ± 10	20 (38%)	43 (81%)	18 (34%)	22 (42%)	N/A	4.5 ± 1.8	N/A
	TEE (n = 51)	76 ± 7	20 (39%)	46 (90%)	15 (29%)	17 (33%)	N/A	4.5 ± 1.6	N/A
Kim 2018	ICE (n = 41)	71.4 ± 9.3	17 (41%)	37 (90%)	11 (27%)	20 (49%)	20 (49%)	4.3 ± 1.4	3.0 ± 1.5
	TEE (n = 103)	72.3 ± 9.2	52 (50)	86 (83%)	26 (25%)	44 (43%)	45 (44%)	4.3 ± 1.4	3.1 ± 1.4
Reis 2018	ICE (n = 26)	N/A	N/A	N/A	N/A	N/A	N/A	N/A	N/A
	TEE (n = 56)	N/A	N/A	N/A	N/A	N/A	N/A	N/A	N/A
Nielsen-Kudsk 2019	ICE (n = 130)	75 ± 8	52 (40%)	N/A	N/A	70 (54)	94 (72)	4.1 ± 1.6	3.2 ± 0.9
	TEE (n = 955)	75 ± 9	334 (35%)	N/A	N/A	334 (35)	688 (72)	4.2 ± 1.6	3.3 ± 1.1
Streb et al.	ICE (n = 11)	77 [7]	6 (54.5%)	9 (81.8%)	3 (27.2%)	5 (45.4%)	9 (81.8%)	5.00 [2]	3.0 [2]
	TEE (n = 12)	73 [15]	8 (66.6%)	11 (91.7%)	3 (25%)	3 (25%)	10 (83.3%)	5.00 [1.50]	2.00 [0.50]
Alkhouli 2020	ICE (n = 90)	75.7 ± 8.0	34 (38%)	83 (92%)	30 (33%)	33 (36%)	N/A	4.7 ± 1.4	2.8 ± 1.2
	TEE (n = 196)	75.2 ± 7.8	87 (44%)	171 (87%)	86 (44%)	84 (43%)	N/A	4.8 ± 1.6	2.9 ± 1.1

ICE = Intracardiac echocardiography, TEE = Transesophageal echocardiography, TIA = Transient ischemic attack. Continuous variables are reported as mean ± standard deviation or median [range or inter-quartile range], dichotomous variables are reported as number (percentage).

Procedural Success



Periprocedural Complications



**Figure 2.** Forest plots showing co-primary outcomes of procedural success and periprocedural complications in left atrial appendage closure using intracardiac echocardiography (ICE) compared to transesophageal echocardiography (TEE). ICE = Intracardiac echocardiography, TEE = Transesophageal echocardiography.

Study characteristics

The meta-analysis included 2620 patients: 679 underwent LAAC using ICE and 1941 using TEE guidance. Five studies were single-center studies while four were multicenter. Only one of the nine studies was a prospective study including 23 patients [19]. Two studies were conducted in USA, one was conducted in Korea and all others were European studies.

Watchman device was the only device used for LAAC in three studies, Amulet was the only device used in 2 studies, Amulet or ACP was used in 2 studies and all three devices were used in 2 studies (Table 2). The mean age of the study population ranged from 71.2 years to 81 years, and 37% were females (Table 3). About 39% of included patients in our analysis had a prior history of stroke or TIA and 70% had a history of prior bleeding. Mean CHA<sub>2</sub>DS<sub>2</sub>-Vasc scores (4.4 ± 0.3 for ICE vs 4.5 ± 0.3 for TEE, P = 0.60) and HAS-BLED scores (3.2 ± 0.4 for ICE

vs 3.1 ± 0.6 for TEE, P = 0.78) were comparable between the two groups.

Primary outcomes

There was no difference in procedural success rate between ICE and TEE groups (97.5% vs 97.2%, RR = 1.01, 95% CI: 0.99-1.02, P = 0.31) (Figure 2). Test of heterogeneity was low (I<sup>2</sup> = 0%). There was a trend towards lower periprocedural complications with ICE compared to TEE (5.2% vs 7.7%, RR = 0.85, 95% CI: 0.59-1.23, P = 0.39) and heterogeneity was low (I<sup>2</sup> = 0%). Table 4 summarizes various periprocedural complications as reported in the included studies.

Secondary outcomes

There was no significant difference in procedure duration (SMD = -0.29, 95% CI: -1.01-0.43, P = 0.43), fluoroscopy time (SMD = -0.03, 95% CI: -0.30-0.23, P = 0.80), or contrast vol-

## ICE vs TEE for LAAC

**Table 4.** Periprocedural complications as reported in the included studies

Study	Periprocedural complications reported							
	Death	Pericardial effusion/ tamponade	Major bleeding	Vascular complications	Device embolization	Stroke/ TIA	Renal failure	MI
Frangieh 2016	+	+	-	+	+	+	+	-
Korsholm 2017	-	+	+	+	+	+	-	-
Berti 2018	-	+	+	-	+	+	-	-
Hemam 2018	+	+	+	-	+	+	-	-
Kim 2018	+	+	-	+	+	+	-	+
Reis 2018	+	+	+	+	+	+	-	-
Nielsen-Kudsk 2019	+	+	+	+	+	+	+	
Streb 2019	-	+	-	+	+	+	-	-
Alkhouli 2020	+	+	-	+	+	+	-	-

MI = Myocardial infarction, TIA = Transient ischemic attack. "+" indicates that the complication was reported in the individual study whereas "-" indicates that the complication was not reported.

ume (SMD = -0.08, 95% CI: -0.83-0.67, P = 0.84) between ICE and TEE groups (**Figure 3A-C**). A non-significant trend towards decreased length of hospital stay was seen in ICE compared with TEE (SMD = -0.24, 95% CI: -0.50-0.02, P = 0.07) (**Figure 3D**).

### Publication bias

The meta-analysis included a small number of studies, and visual inspection of the funnel plots did not suggest publication bias for the primary outcomes (**Figure 4**).

### Discussion

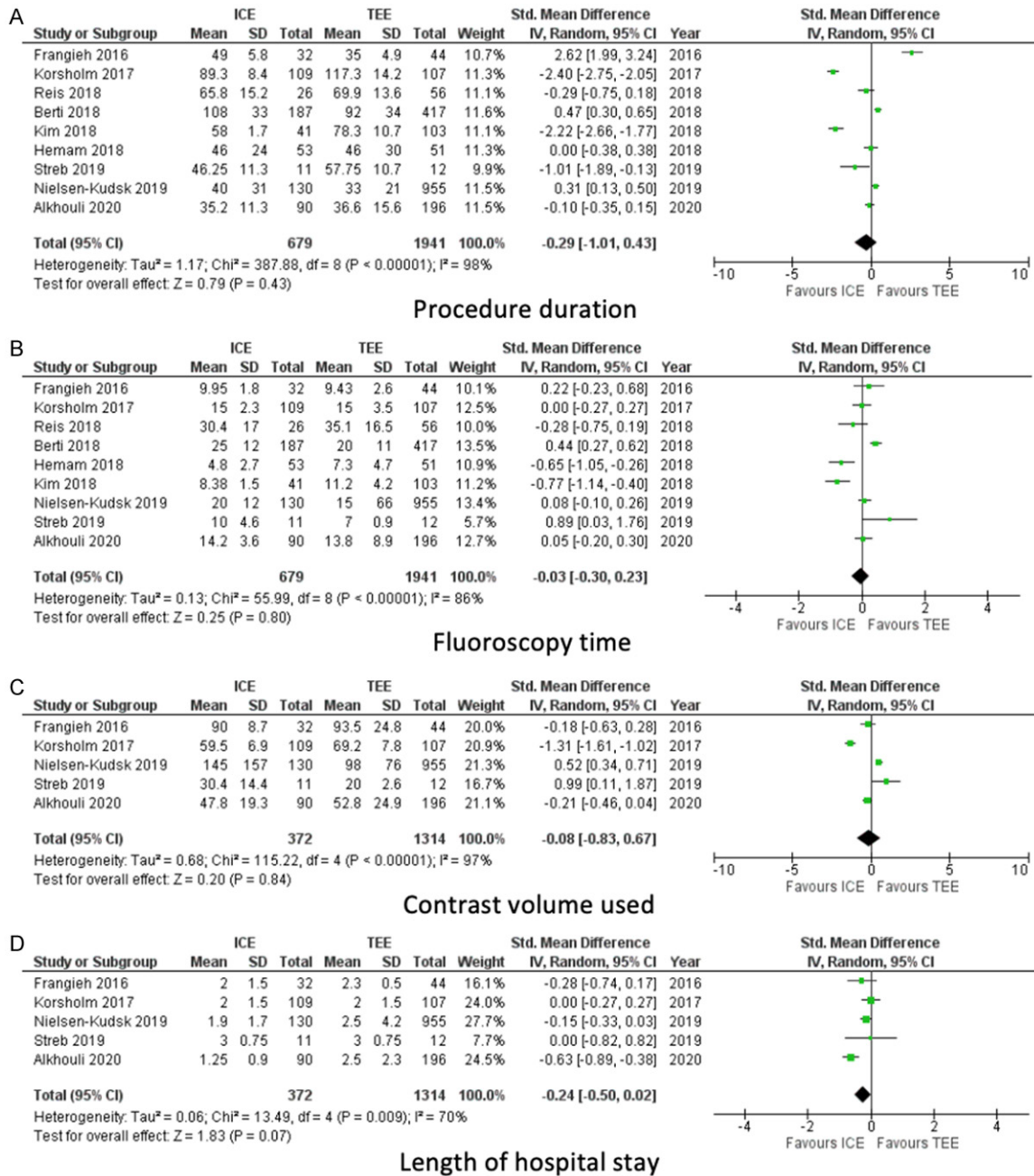
The main findings in this meta-analysis are that percutaneous LAAC using ICE was associated with similar procedure success, and complication rates when compared with TEE with no significant difference in procedure or, fluoroscopy time. Our extensive literature search identified 2 other systematic reviews and meta-analyses that also demonstrated similar acute procedural success rates without an increase in risk of complications [21, 22]. Compared with these two prior analyses, our analysis included one additional study which increased the power to estimate an actual difference between the two imaging modalities.

TEE is currently the standard imaging modality and is the most frequently employed modality during percutaneous LAAC across centers worldwide. Nonetheless, several logistical and procedural challenges of TEE merit consideration. These include not only the availability

of echocardiography and anesthesia staff but more importantly, the effects of GA on the old and frail population that is typically referred for LAAC. Increasingly, structural heart interventions are being performed using a 'minimalistic' approach. For example, among 120,080 patients who underwent transcatheter aortic valve replacement between January 2016 and March 2019, the use of conscious sedation for the procedure increased from 33% to 64% [23]. During that time period conscious sedation was associated with a decrease in hospital length of stay, in-hospital mortality and 30-day mortality as compared to GA. Moreover, TEE itself is associated with risks. In a prospective study involving 50 patients, including 24 who underwent LAAC, Freitas-Ferraz et al. found that 86% of the patients had a new injury on post-procedure esophagogastroduodenoscopy, with 40% having a complex lesion such as intramural hematoma or mucosal laceration [24]. Thus, avoidance of GA and TEE in high-risk individuals appear logical.

ICE on the other hand, eliminates the need for GA and can be performed utilizing local anesthesia or moderate sedation. However, ICE requires a separate venous access which may increase the risk of vascular complications and may lead to an increase in hospital stay and costs. LAA image quality and reproducibility with ICE imaging from the right atrium (RA) remains an area of concern during LAAC deployment. This can be improved by obtaining images from the left atrium (LA) [25]. The ICE catheter can be advanced from the RA into LA utiliz-

## ICE vs TEE for LAAC

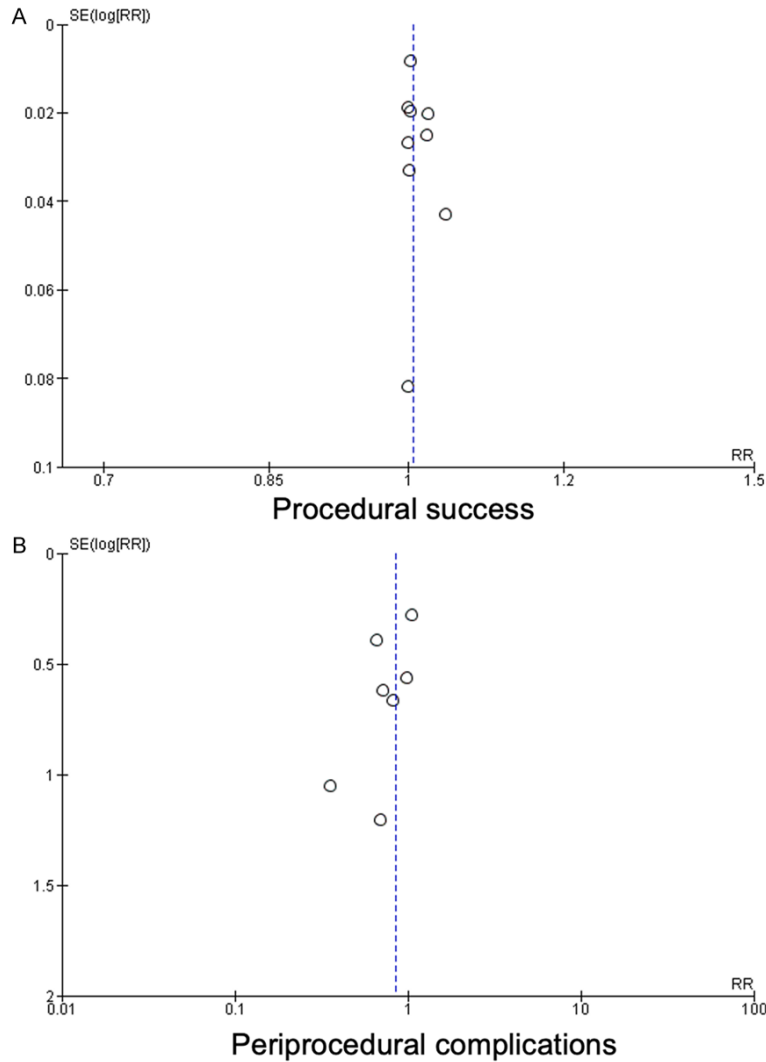


**Figure 3.** Forest plots showing secondary outcomes of procedure duration, fluoroscopy time, contrast volume used and hospital length of stay in left atrial appendage closure using intracardiac echocardiography (ICE) compared to transesophageal echocardiography (TEE). ICE = Intracardiac echocardiography, TEE = Transesophageal echocardiography.

ing the same transseptal puncture for the LAAC device sheath or with a separate transseptal puncture. All studies in this analysis except one (Kim et al.) used a single transseptal puncture technique without any increase in complication rates. LA was the sole position for ICE catheter in guiding LAAC device deployment in 8

studies in this analysis. High procedural success rate further supports the fact that ICE in LA position can be utilized in deploying LAAC devices with similar efficacy as TEE. However, operators must use caution while advancing ICE catheter into LA since additional manipulation can be a cause of atrial wall injury.

## ICE vs TEE for LAAC



**Figure 4.** Funnel plots showing no evidence of publication bias on visual inspection for co-primary outcomes of procedural success and periprocedural complications.

Other aspects of routine TEE imaging, critical for a successful procedure, can similarly be performed with ICE guidance. ICE imaging from a right ventricular outflow tract or pulmonary artery position can rule out a thrombus in LAA prior to transseptal puncture. Accurate measurements of LAA can be made thus assisting the operator in choosing the appropriately sized device. ICE has previously been shown to strongly correlate with TEE for length, width, and area of LAA [26]. After deployment of the device, assessment of peri-device leak can be made by use of color doppler flow imaging [27]. However, a lower Nyquist limit between 20-30 cm/s is recommended. Also, assessment of pericardial effusion can be done while the ICE

catheter is positioned in the right ventricle across the tricuspid valve.

Another concern with ICE is the high cost associated with the equipment. However as shown by Hemam et al. and Alkhouli et al., the increased hospitalization charges associated with ICE were offset by decreased professional charges due to a reduction in the number of personnel involved with the procedure [15, 20]. Thus, global charges for LAAC were comparable whether the procedure was performed using ICE or TEE guidance. Finally, there may be a significant learning curve associated with ICE. However, this did not translate into an increased procedural duration as shown by our analysis.

### Limitations

Though the findings of our analysis are intriguing, they must be interpreted with caution and several limitations are worth noting. First, all studies except one were retrospective observational studies which introduced the potential for selection bias.

Second, reported periprocedural complications varied from one study to another and the definitions of these complications were not readily available. Third, the confounding effect of pre-procedural imaging modalities (TEE or CCTA) in optimal size selection of LAAC device and thus subsequent successful deployment cannot be fully eliminated. Fourth, the impact of type of LAAC device on primary outcomes could not be determined from available data. Presently, Watchman device is the only Food and Drug Administration approved device for use in USA while ACP, Amulet and Watchman devices are all available for commercial use in Europe. Fifth, it is unclear if utilization of ICE had any impact on patient satisfaction since this variable may be difficult



to measure and was not reported in any of the studies. Finally, all meta-analyses are limited by the inherent issue of publication bias.

### Conclusion

Our analysis suggests that LAAC can be performed under ICE guidance with equal efficacy and safety compared to TEE.

### Disclosure of conflict of interest

Dr. Pradeep Yadav: Consultant for Edwards Lifesciences, Abbott Vascular, Shockwave Medical, Stock options Shockwave Medical. Dr. J Dawn Abbott: Research grants with no direct compensation from Abbott vascular, Sinomed, Astrazeneca, Bristol myers squibb, Biosensors Research USA Inc. Dr. Dhanunjaya Lakkireddy: Has served as a steering committee member for the Amulet and Amaze IDE studies; and has received consulting fees from Abbott. Dr. Manish Parikh: Advisory board and speaker bureau for Medtronic, Boston Scientific and Abbott Vascular. Dr. Poonam Velagapudi: Speakers bureau, Abiomed.

**Address correspondence to:** Dr. Poonam Velagapudi, Division of Cardiology, University of Nebraska Medical Center, 982265 Nebraska Medical Center, Omaha 68198-2265, NE, USA. E-mail: poonamchou@gmail.com

### References

- [1] Blackshear JL and Odell JA. Appendage obliteration to reduce stroke in cardiac surgical patients with atrial fibrillation. *Ann Thorac Surg* 1996; 61: 755-759.
- [2] Reddy VY, Sievert H, Halperin J, Doshi SK, Buchbinder M, Neuzil P, Huber K, Whisenant B, Kar S, Swarup V, Gordon N and Holmes D; PROTECT AF Steering Committee and Investigators. Percutaneous left atrial appendage closure vs warfarin for atrial fibrillation: a randomized clinical trial. *JAMA* 2014; 312: 1988-1998.
- [3] Holmes DR, Kar S, Price MJ, Whisenant B, Sievert H, Doshi SK, Huber K and Reddy VY. Prospective randomized evaluation of the watchman left atrial appendage closure device in patients with atrial fibrillation versus long-term warfarin therapy: the PREVAIL trial. *J Am Coll Cardiol* 2014; 64: 1-12.
- [4] Boersma LV, Schmidt B, Betts TR, Sievert H, Tamburino C, Teiger E, Pokushalov E, Kische S, Schmitz T, Stein KM and Bergmann MW; EWOLUTION investigators. Implant success and safety of left atrial appendage closure with the WATCHMAN device: peri-procedural outcomes from the EWOLUTION registry. *Eur Heart J* 2016; 37: 2465-74.
- [5] Turagam MK, Velagapudi P, Kar S, Holmes D, Reddy VY, Refaat MM, Di Biase L, Al-Ahmed A, Chung MK, Lewalter T, Edgerton J, Cox J, Fisher J, Natale A and Lakkireddy DR. Cardiovascular therapies targeting left atrial appendage. *J Am Coll Cardiol* 2018; 72: 448-463.
- [6] Jazayeri MA, Vuddanda V, Turagam MK, Parikh V, Lavu M, Atkins D, Earnest M, Di Biase L, Natale A, Wilber D, Reddy YM and Lakkireddy DR. Safety profiles of percutaneous left atrial appendage closure devices: an analysis of the food and drug administration manufacturer and user facility device experience (MAUDE) database from 2009 to 2016. *J Cardiovasc Electrophysiol* 2018; 29: 5-13.
- [7] Freeman JV, Varosy P, Price MJ, Slotwiner D, Kusumoto FM, Rammohan C, Kavinsky CJ, Turi ZG, Akar J, Koutras C, Curtis JP and Masoudi FA. The NCDR left atrial appendage occlusion registry. *J Am Coll Cardiol* 2020; 75: 1503-1518.
- [8] Prakash R and Saw J. Imaging for percutaneous left atrial appendage closure. *Catheter Cardiovasc Interv* 2018; 92: 437-450.
- [9] Pison L, Potpara TS, Chen J, Larsen TB, Bongioni MG and Blomström-Lundqvist C; Scientific Initiative Committee, European Heart Rhythm Association. Left atrial appendage closure-indications, techniques, and outcomes: results of the European Heart Rhythm Association survey. *Europace* 2015; 17: 642-646.
- [10] Liberati A, Altman DG, Tetzlaff J, Mulrow C, Gøtzsche PC, Ioannidis JP, Clarke M, Devereaux PJ, Kleijnen J and Moher D. The PRISMA statement for reporting systematic reviews and meta-analyses of studies that evaluate health-care interventions: explanation and elaboration. *BMJ* 2009; 339: b2700.
- [11] Higgins JP, Thompson SG, Deeks JJ and Altman DG. Measuring inconsistency in meta-analyses. *BMJ* 2003; 327: 557-560.
- [12] Frangieh AH, Alibegovic J, Templin C, Gaemperli O, Obeid S, Manka R, Holy EW, Maier W, Lüscher TF and Binder RK. Intracardiac versus transesophageal echocardiography for left atrial appendage occlusion with watchman. *Catheter Cardiovasc Interv* 2017; 90: 331-338.
- [13] Korsholm K, Jensen JM and Nielsen-Kudsk JE. Intracardiac echocardiography from the left atrium for procedural guidance of transcatheter left atrial appendage occlusion. *JACC Cardiovasc Interv* 2017; 10: 2198-2206.
- [14] Berti S, Pastormerlo LE, Santoro G, Brscic E, Montorfano M, Vignali L, Danna P, Tondo C, Rezzaghi M, D'Amico G, Stabile A, Saccà S, Am J Cardiovasc Dis 2020;10(5):538-547

## ICE vs TEE for LAAC

- Patti G, Rapacciuolo A, Poli A, Golino P, Magnavacchi P, Meucci F, Pezzulich B, Stolcova M and Tarantini G. Intracardiac versus transesophageal echocardiographic guidance for left atrial appendage occlusion: the LAAO Italian multicenter registry. *JACC Cardiovasc Interv* 2018; 11: 1086-1092.
- [15] Hemam ME, Kuroki K, Schurmann PA, Dave AS, Rodríguez DA, Sáenz LC, Reddy VY and Valderrábano M. Left atrial appendage closure with the watchman device using intracardiac vs transesophageal echocardiography: procedural and cost considerations. *Heart Rhythm* 2019; 16: 334-342.
- [16] Kim DY, Shin SY, Kim JS, Kim SH, Kim YH and Lim HE. Feasibility of intracardiac echocardiography imaging from the left superior pulmonary vein for left atrial appendage occlusion. *Int J Cardiovasc Imaging* 2018; 34: 1571-1579.
- [17] Reis L, Paiva L, Costa M, Silva J, Teixeira R, Botelho A, Dinis P, Madeira M, Ribeiro J, Nascimento J and Gonçalves L. Registo de encerramento percutâneo do apêndice auricular esquerdo e experiência inicial com ecografia intracardiaca. *Rev Port Cardiol* 2018; 37: 763-772.
- [18] Nielsen-Kudsk JE, Berti S, De Backer O, Aguirre D, Fassini G, Cruz-Gonzalez I, Grassi G and Tondo C. Use of intracardiac compared with transesophageal echocardiography for left atrial appendage occlusion in the amulet observational study. *JACC Cardiovasc Interv* 2019; 12: 1030-1039.
- [19] Streb W, Mitreęa K, Podolecki T, Morawski S, Szulik M, Jędrzejczyk-Patej E, Kukulski T and Kalarus Z. Comparison of transesophageal and intracardiac echocardiography in guiding percutaneous left atrial appendage closure with an Amplatzer Amulet device. *Postepy Kardiol Interwencyjnej* 2019; 15: 446-454.
- [20] Alkhouli M, Chaker Z, Alqahtani F, Raslan S and Raybuck B. Outcomes of routine intracardiac echocardiography to guide left atrial appendage occlusion. *JACC Clin Electrophysiol* 2020; 6: 393-400.
- [21] Velagapudi P, Turagam MK, Kolte D, Khera S, Gupta T, Garg J, Abbott JD, George I, Khalique O, Vahl T, Nazif T, Lakkireddy D, Kodali S and Sommer R. Intracardiac vs transesophageal echocardiography for percutaneous left atrial appendage occlusion: a meta-analysis. *J Cardiovasc Electrophysiol* 2019; 30: 461-467.
- [22] Akella K, Murtaza G, Turagam M, Sharma S, Madoukh B, Amin A, Gopinathannair R and Lakkireddy D. Evaluating the role of transesophageal echocardiography (TEE) or intracardiac echocardiography (ICE) in left atrial appendage occlusion: a meta-analysis. *J Interv Card Electrophysiol* 2020; [Epub ahead of print].
- [23] Butala NM, Chung M, Secemsky EA, Manandhar P, Marquis-Gravel G, Kosinski AS, Vemulapalli S, Yeh RW and Cohen DJ. Conscious sedation versus general anesthesia for transcatheter aortic valve replacement. *JACC Cardiovasc Interv* 2020; 13: 1277-1287.
- [24] Freitas-Ferraz AB, Bernier M, Vaillancourt R, Ugalde PA, Nicodème F, Paradis JM, Champagne J, O'Hara G, Junquera L, del Val D, Muntané-Carol G, O'Connor K, Beaudoin J and Rodés-Cabau J. Safety of transesophageal echocardiography to guide structural cardiac interventions. *J Am Coll Cardiol* 2020; 75: 3164-3173.
- [25] Paiva LV, Costa MP, Barra SC and Gonçalves L. Intracardiac echography for left atrial appendage closure: a step-by-step tutorial. *Catheter Cardiovasc Interv* 2019; 93: E302-E310.
- [26] Anter E, Silverstein J, Tschabrunn CM, Shvilkin A, Haffajee CI, Zimetbaum PJ, Buxton AE, Josephson ME, Gelfand E and Manning WJ. Comparison of intracardiac echocardiography and transesophageal echocardiography for imaging of the right and left atrial appendages. *Heart Rhythm* 2014; 11: 1890-1897.
- [27] Ren JF, Callans DJ and Marchlinski FE. Intracardiac echocardiographic imaging of the left atrial appendage and detection of a peridevice leak after device occlusion. *JACC Cardiovasc Interv* 2015; 8: 124-126.